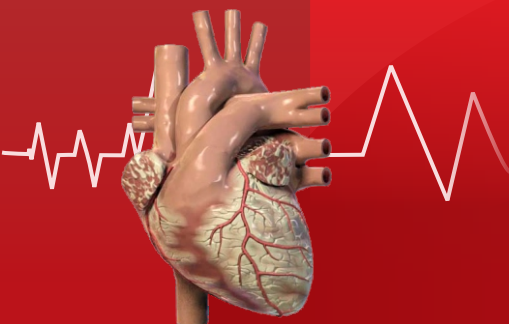

Healthy Heart

Volume-5 | Issue-56 | July 5, 2014

Price : ₹ 5/-

Honorary Editor :

Dr. Dhiren Shah



From the desk of Hon. Editor:

Dear Friends,

In developed and developing nations, aortic stenosis (AS) is the most common valvular heart disease presentation, and its prevalence is increasing due to aging populations. In India we will come across more and more patients with degenerative Aortic stenosis as the Indian population life expectancy increases. Our understanding of calcific AS has changed dramatically, from a concept of a "mechanical" disease of aging strictly limited with the valve, to a modern concept of a progressive disease process, with similarities to atherosclerosis. Because AS is a fatal disease when left untreated, replacement of the degenerative and stenotic valve with an artificial valve (bio-prosthetic or mechanical) is the recommended treatment for patients with symptomatic, severe AS. Therefore, the accurate diagnosis of the disease and determination of its hemodynamic severity are clinically essential in clinical decision-making. Technological advances have made it possible to even treat the most moribund patient and give them a good productive life.

- Dr. Dhiren Shah

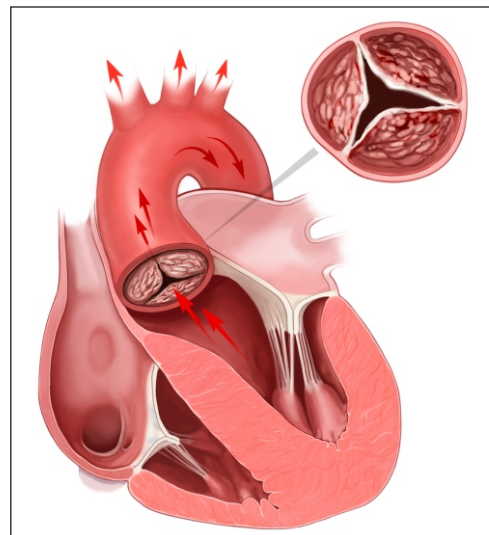
Options for managing severe aortic stenosis: A case-based review

A PROGRESSIVE DISEASE OF THE ELDERLY

Aortic stenosis is the most common acquired valvular disease in the United States, and its incidence and prevalence are rising as the population ages. Epidemiologic studies suggest that 2% to 7% of all patients over age 65 have it.

The natural history of the untreated disease is well established, with several case series showing an average decrease of 0.1 cm² per year in aortic valve area and an increase of 7 mm Hg per year in the pressure gradient across the valve once the diagnosis is made. Development of angina, syncope, or heart failure is associated with adverse clinical outcomes, including death, and warrants prompt intervention with aortic valve replacement. Without intervention, the mortality rates reach as high as 75% in 3 years once symptoms develop.

Statins, bisphosphonates, and angiotensin-converting enzyme inhibitors have been used in attempts to slow or reverse the progression of aortic stenosis. However, studies of these drugs have had mixed results, and no definitive benefit has been shown. Surgical aortic valve replacement, on the other hand, normalizes the life expectancy of patients with aortic stenosis to that of age- and



sex-matched controls and remains the gold standard therapy for patients who have symptoms.

Traditionally, valve replacement has involved open heart surgery, since it requires direct visualization of the valve while the patient is on cardiopulmonary bypass. Unfortunately, many patients have multiple comorbid conditions and therefore are not candidates for open heart surgery. Options for these patients include aortic valvuloplasty and transcatheter aortic valve replacement. While there is considerable experience with aortic valvuloplasty, transcatheter aortic valve replacement is relatively new. In large randomized trials and registries, the transcatheter procedure has been

Cardiologists

Dr. Ajay Naik (M) +91-98250 82666 Dr. Milan Chag (M) +91-98240 22107
Dr. Satya Gupta (M) +91-99250 45780 Dr. Urmil Shah (M) +91-98250 66939
Dr. Vineet Sankhla (M) +91-99250 15056 Dr. Hemang Baxi (M) +91-98250 30111
Dr. Gunvant Patel (M) +91-98240 61266 Dr. Anish Chandarana (M) +91-98250 96922
Dr. Keyur Parikh (M) +91-98250 26999

Congenital & Structural Heart Disease Specialist

Dr. Kashyap Sheth (M) +91-99246 12288 Dr. Milan Chag (M) +91-98240 22107

Cardiothoracic & Vascular Surgeons

Dr. Dhaval Naik (M) +91-90991 11133
Dr. Saurabh Jaiswal (M) +91-95867 25827
Dr. Dhiren Shah (M) +91-98255 75933

Pediatric & Structural Heart Surgeons

Dr. Shaunak Shah (M) +91-98250 44502

Cardiovascular, Thoracic & Thoracoscopic Surgeon

Dr. Pranav Modi (M) +91-99240 84700

Cardiac Anaesthetists

Dr. Hiren Dholakia (M) +91-95863 75818
Dr. Chintan Sheth (M) +91-91732 04454
Dr. Niren Bhavsar (M) +91-98795 71917

Neonatologist and Pediatric Intensivist

Dr. Amit Chitaliya (M) +91-90999 87400

Cardiac Electrophysiologist

Dr. Ajay Naik (M) +91-98250 82666
Dr. Vineet Sankhla (M) +91-99250 15056

shown to significantly improve long-term survival compared with medical management alone in inoperable patients and to have benefit similar to that of surgery in the high-risk population.

CASE 1: SEVERE, SYMPTOMATIC STENOSIS IN A GOOD SURGICAL CANDIDATE

Mr. A, age 83, presents with shortness of breath and peripheral edema that have been worsening over the past several months. His pulse rate is 64 beats per minute and his blood pressure is 110/90 mm Hg. Auscultation reveals an absent aortic second heart sound with a late peaking systolic murmur that increases with expiration.

On echocardiography, his left ventricular ejection fraction is 55%, peak transaortic valve gradient 88 mm Hg, mean gradient 60 mm Hg, and effective valve area 0.6 cm². He undergoes catheterization of the left side of his heart, which shows normal coronary arteries.

Mr. A also has hypertension and hyperlipidemia; his renal and pulmonary functions are normal.

How would you manage Mr. A's aortic stenosis?

Symptomatic aortic stenosis leads to adverse clinical outcomes if managed medically without mechanical intervention, but patients who undergo aortic valve replacement have age-corrected postoperative survival rates that are nearly normal. Furthermore, thanks to improvements in surgical techniques and perioperative management, surgical mortality rates have decreased significantly in recent years and now range from 1% to 8%. The accumulated evidence showing clear

superiority of a surgical approach over medical therapy has greatly simplified the therapeutic algorithm.

Consequently, the current guidelines from the American College of Cardiology and American Heart Association (ACC/AHA) give surgery a class I indication (evidence or general agreement that the procedure is beneficial, useful, and effective) for symptomatic severe aortic stenosis. This level of recommendation also applies to patients who have severe but asymptomatic aortic stenosis who are undergoing other types of cardiac surgery and also to patients with severe aortic stenosis and left ventricular dysfunction (defined as an ejection fraction < 50%).

CASE 2: SYMPTOMS AND LEFT VENTRICULAR DYSFUNCTION

Ms. B, age 79, has hypertension and hyperlipidemia and now presents to the outpatient department with worsening shortness of breath and chest discomfort. Electrocardiography shows significant left ventricular hypertrophy and abnormal repolarization. Left heart catheterization reveals mild nonobstructive coronary artery disease.

Echocardiography reveals an ejection fraction of 25%, severe left ventricular hypertrophy, and global hypokinesis. The aortic valve leaflets appear heavily calcified, with restricted motion. The peak and mean gradients across the aortic valve are 40 and 28 mm Hg, and the valve area is 0.8 cm². Right heart catheterization shows a cardiac output of 3.1 L/min.

Does this patient's aortic stenosis account for her clinical presentation?

Managing patients who have suspected severe aortic stenosis, left ventricular

dysfunction, and low aortic valve gradients can be challenging. Although data for surgical intervention are not as robust for these patient subsets as for patients like Mr. A, several case series have suggested that survival in these patients is significantly better with surgery than with medical therapy alone.

Specific factors predict whether patients with ventricular dysfunction and low gradients will benefit from aortic valve replacement. Dobutamine stress echocardiography is helpful in distinguishing true severe aortic stenosis from "pseudostenosis," in which leaflet motion is restricted due to primary cardiomyopathy and low flow. Distinguishing between true aortic stenosis and pseudostenosis is of paramount value, as surgery is associated with improved long-term outcomes in patients with true aortic stenosis (even though they are at higher surgical risk), whereas those with pseudostenosis will not benefit from surgery.

Infusion of dobutamine increases the flow across the aortic valve (if the left ventricle has contractile reserve; more on this below), and an increasing valve area with increasing doses of dobutamine is consistent with pseudostenosis. In this situation, treatment of the underlying cardiomyopathy is indicated as opposed to replacement of the aortic valve.

Contractile reserve is defined as an increase in stroke volume (> 20%), valvular gradient (> 10 mm Hg), or peak velocity (> 0.6 m/s) with peak dobutamine infusion. The presence of contractile reserve in patients with aortic stenosis identifies a high-risk

group that benefits from aortic valve replacement.

Treatment of patients who have inadequate reserve is controversial. In the absence of contractile reserve, an adjunct imaging study such as computed tomography may be of value in detecting calcified valve leaflets, as the presence of calcium is associated with true aortic stenosis. Comorbid conditions should be taken into account as well, given the higher surgical risk in this patient subset, as aortic valve replacement in this already high-risk group of patients might be futile in some cases.

The ACC/AHA guidelines now give dobutamine stress echocardiography a class IIa indication (meaning the weight of the evidence or opinion is in favor of usefulness or efficacy) for determination of contractile reserve and valvular stenosis for patients with an ejection fraction of 30% or less or a mean gradient of 40 mm Hg or less.

Ms. B underwent dobutamine stress echocardiography. It showed increases in ejection fraction, stroke volume, and transvalvular gradients, indicating that she did have contractile reserve and true severe aortic stenosis. Consequently, she was referred for surgical aortic valve replacement.

CASE 3: MODERATE STENOSIS AND THREE-VESSEL CORONARY ARTERY DISEASE

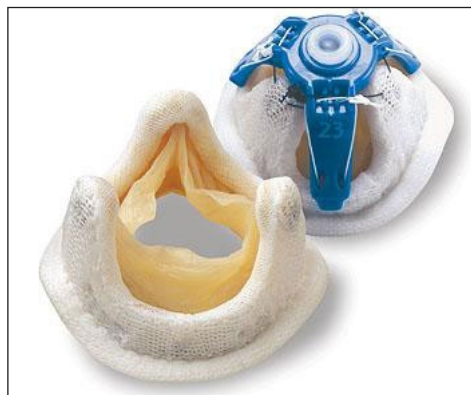Mr. C, age 81, has hypertension and hyperlipidemia. He now presents to the emergency department with chest discomfort that began suddenly, awakening him from sleep. His presenting electrocardiogram shows nonspecific changes, and he is

diagnosed with non-ST-elevation myocardial infarction. He undergoes left heart catheterization, which reveals severe three-vessel coronary artery disease.

Echocardiography reveals an ejection fraction of 55% and aortic stenosis, with an aortic valve area of 1.2 cm², a peak gradient of 44 mm Hg, and a mean gradient of 28 mm Hg.

How would you manage his aortic stenosis?

Moderate aortic stenosis in a patient who needs surgery for severe triple-vessel coronary artery disease, other valve diseases, or aortic disease raises the question of whether aortic valve replacement should be performed in



conjunction with these surgeries. Although these patients would not otherwise qualify for aortic valve replacement, the fact that they will undergo a procedure that will expose them to the risks associated with open heart surgery makes them reasonable candidates. Even if the patient does not need aortic valve replacement right now, aortic stenosis progresses at a predictable rate—the valve area decreases by a mean of 0.1 cm²/year and the gradients increase by 7 mm Hg/year. Therefore, clinical judgment should be exercised so that the patient

will not need to undergo open heart surgery again in the near future.

The ACC/AHA guidelines recommend aortic valve replacement for patients with moderate aortic stenosis undergoing coronary artery bypass grafting or surgery on the aorta or other heart valves, giving it a class IIa indication. This recommendation is based on several retrospective case series that evaluated survival, the need for reoperation for aortic valve replacement, or both in patients undergoing coronary artery bypass grafting.

The ACC/AHA guidelines state that aortic valve replacement “may be considered” in patients undergoing coronary artery bypass grafting who have mild aortic stenosis (mean gradient <30 mm Hg or jet velocity <3 m/s) when there is evidence, such as moderate or severe valve calcification, that progression may be rapid (level of evidence C: based only on consensus opinion of experts, case studies or standard of care).

Mr. C, who has moderate aortic stenosis, underwent aortic valve replacement in conjunction with three-vessel bypass grafting.

CASE 4: ASYMPTOMATIC BUT SEVERE STENOSIS

Mr. D, age 74, has hypertension, hyperlipidemia, and aortic stenosis. He now presents to the outpatient department for his annual echocardiogram to follow his aortic stenosis. He has a sedentary lifestyle but feels well performing activities of daily living. He denies dyspnea on exertion, chest pain, or syncope.

His echocardiogram reveals an effective

aortic valve area of 0.7 cm², peak gradient 90 mm Hg, and mean gradient 70 mm Hg. There is evidence of severe left ventricular hypertrophy, and the valve leaflets show bulky calcification and severe restriction. An echocardiogram performed at the same institution a year earlier revealed gradients of 60 and 40 mm Hg.

Blood is drawn for laboratory tests, including N-terminal pro-brain natriuretic peptide, which is 350 pg/mL (reference range for his age < 125 pg/mL). He is referred for a treadmill stress test, which elicits symptoms at a moderate activity level.

How would you manage his aortic stenosis?

Aortic valve replacement can be considered in patients who have asymptomatic but severe aortic stenosis with preserved left ventricular function (class IIb indication).

Clinical assessment of asymptomatic aortic stenosis can be challenging, however, as patients may underreport their symptoms or decrease their activity levels to avoid symptoms. Exercise testing in such patients can elicit symptoms, unmask diminished exercise capacity, and help determine if they should be referred for surgery. Natriuretic peptide levels have been shown to correlate with the severity of aortic stenosis, and more importantly, to help predict symptom onset, cardiac death, and need for aortic valve replacement.

Some patients with asymptomatic but severe aortic stenosis are at higher risk of morbidity and death. High-risk subsets include patients with rapid progression of aortic stenosis and those with critical aortic stenosis characterized by an aortic valve area less

than 0.60 cm², mean gradient greater than 60 mm Hg, and jet velocity greater than 5.0 m/s. It is reasonable to offer these patients surgery if their expected operative mortality risk is less than 1.0%.

Mr. D has evidence of rapid progression as defined by an increase in aortic jet velocity of more than 0.3 m/s/year. He is at low surgical risk and was referred for elective aortic valve replacement.

CASE 5: TOO FRAIL FOR SURGERY

Mr. E, age 84, has severe aortic stenosis (valve area 0.6 cm², peak and mean gradients of 88 and 56 mm Hg), coronary artery disease status post coronary artery bypass grafting, moderate chronic obstructive pulmonary disease (forced expiratory volume in 1 second 0.8 L), chronic kidney disease (serum creatinine 1.9 mg/dL), hypertension, hyperlipidemia, and diabetes mellitus. He has preserved left ventricular function. He presents to the outpatient department with worsening shortness of breath and peripheral edema over the past several months. Your impression is that he is very frail. How would you manage Mr. E's aortic stenosis?

Advances in surgical techniques and perioperative management over the years have enabled higher-risk patients to undergo surgical aortic valve replacement with excellent out-comes. Yet many patients still cannot undergo surgery because their risk is too high. Patients ineligible for surgery have traditionally been treated medically—with poor out-comes—or with balloon aortic valvuloplasty to palliate symptoms.

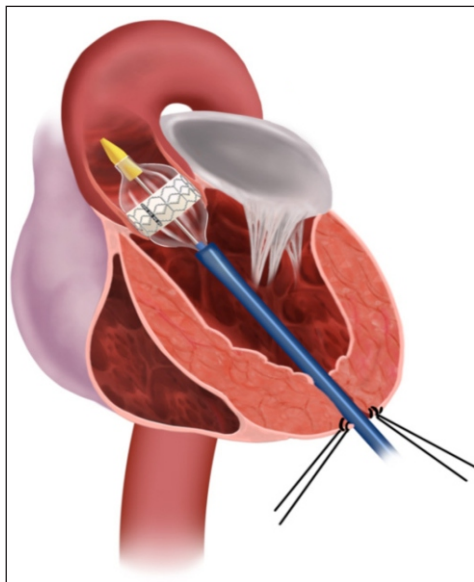
Transcatheter aortic valve replacement, approved by the US Food and Drug Administration (FDA) in 2011, now

provides another option for these patients. In this procedure, a bioprosthetic valve mounted on a metal frame is implanted over the native stenotic valve.

In the Placement of Aortic Transcatheter Valves (PARTNER) trial, patients who could not undergo surgery who underwent transcatheter replacement with this valve had a significantly better survival rate than patients treated medically. Use of this valve has also been compared against conventional surgical aortic valve replacement in high-risk patients and was found to have similar long-term outcomes. It was on the basis of this trial that this valve was granted approval for patients who cannot undergo surgery.

The standard of care for high-risk patients remains surgical aortic valve replacement, although it remains to be seen whether transcatheter replacement will be made available as well to patients eligible for surgery in the near future. There are currently no randomized data for transcatheter aortic valve replacement in patients at moderate to low surgical risk, and these patients should not be considered for this procedure.

Although the initial studies are encouraging for patients who cannot undergo surgery and who are at high risk without it, several issues and concerns remain. Importantly, the long-term durability of the transcatheter valve and longer-term outcomes remain unknown. Furthermore, the risk of vascular complications remains high (10% to 15%), dictating the need for careful patient selection. There are also concerns about the risks of stroke and of paravalvular aortic insufficiency. These issues are being investigated and addressed, however, and we hope that



with increasing operator experience and improvements in the technique, outcomes will be improved.

CASE 6: LIFE-LIMITING COMORBID ILLNESS

Mr. F, age 77, has multiple problems: severe aortic stenosis (aortic valve area 0.6 cm²; peak and mean gradients of 92

and 59 mm Hg), stage IV pancreatic cancer, coronary artery disease status post coronary artery bypass grafting, chronic kidney disease (serum creatinine 1.9 mg/dL), hypertension, and hyperlipidemia. He presents to the outpatient department with shortness of breath at rest, orthopnea, effort intolerance, and peripheral edema over the past several months.

On physical examination rales in both lung bases can be heard. Left heart catheterization shows patent bypass grafts.

How would you manage Mr. F's aortic stenosis?

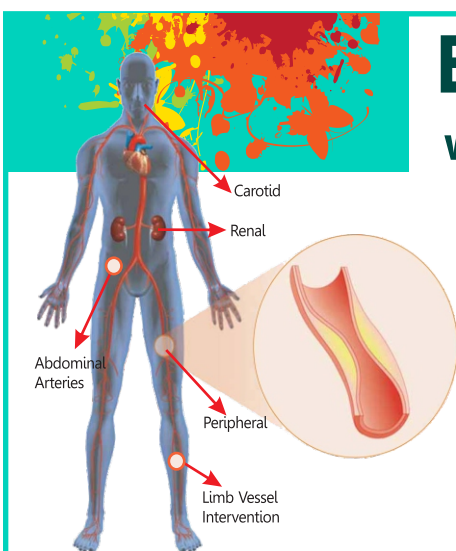
Aortic valve replacement is not considered an option in patients with noncardiac illnesses and comorbidities that are life-limiting in the near term. Under these circumstances, aortic valvuloplasty can be offered as a means of palliating symptoms or, if the comorbid conditions can be modified,

as a bridge to more definitive treatment with aortic valve replacement. The risk of death during the procedure ranged from 3% to 13.5% in several case series, with a 30-day survival rate greater than 85%. However, the hemodynamic and symptomatic improvement is only short-term, as valve area and gradients gradually worsen within several months. Consequently, balloon valvuloplasty is considered a palliative approach.

Mr. F has a potentially life-limiting illness, ie, cancer, which would make him a candidate for aortic valvuloplasty rather than replacement. He can be referred for evaluation for this procedure in hopes of palliating his symptoms by relieving his dyspnea and improving his quality of life.

CIMS Cardiac Surgery Team

Dr. Dhiren Shah	Dr. Pranav Modi
Dr. Dhaval Naik	Dr. Hiren Dholakia
Dr. Saurabh Jaiswal	Dr. Chintan Sheth
Dr. Shaunak Shah	Dr. Niren Bhavsar



Endovascular Peripheral Workshop

with **Dr. Ashit Jain, USA**

August 21-22, 2014

PATIENTS WHO ARE ELIGIBLE

- Carotid Artery Stenosis
- Renal Artery Stenosis
- Acute Limb Ischemia
- Critical Limb Ischemia
- Varicose Veins
- Dialysis Access Procedures
- Pulmonary Embolism
- Thoracic Outlet Syndrome
- Uterine Fibroids
- Vascular Malformations
- Venous Insufficiency and Venous Ulcers
- Claudication
- Femoropopliteal Disease
- Brachiocephalic Arterial Disease
- Venous Thromboembolic Disease
- Thoracic Abdominal Aortic Aneurysms
- Mesenteric Disease
- Catheter-Based Interventions for Failing Hemodialysis Accesses
- Infrapopliteal Peripheral Arterial Disease
- Intracranial Arterial Stenotic Disease
- Vertebral Arterial Disease

Organized by



CIMS Hospital, Nr. Shukan Mall, Off Science City Road, Sola, Ahmedabad-380060. **Phone** : +91-79-2771 2771-75 (5 lines)
For appointment call : +91-79-3010 1200, 3010 1008 (9 am-5 pm)
Mobile : +91-98250 66661 or **email on** opd.rec@cimshospital.org
email : info@cims.me **web** : www.cims.me

Daily screening camp of the concerned patients is being held from

June 15, 2014 onwards at CIMS Hospital. Time: 2.00 pm - 6.00 pm

PATIENTS WILL BE PROVIDED FOLLOWING FREE SERVICES:

- 1. Consultation 2. ABI 3. Doppler (Arterial or Varicose Veins - if indicated)**

You may call any of our CIMS Cardiologists listed on the front page



JIC 2015 at a Glance

Important Announcement

Over 1000 registrations confirmed

Last date of refundable registration for MD Physicians is August 31, 2014.

Day - 1 January 23, 2015 - Main Session

- ☐ Introduction Session
- ☐ Coronary Artery Disease / Acute Coronary Syndromes
- ☐ Plenary Lectures by International Speakers
- ☐ Hypertension / Lipids & Cardiovascular Risk Management
- ☐ Medical Devices in Cardiology / Interventional Cardiology
- ☐ Debates
- ☐ Special Topics


Day - 1 January 23, 2015 - Satellite Sessions

- ☐ Pharmaology & Therapeutics - 1 & 2
- ☐ Cardiology Guidelines
- ☐ Peripheral/ Endovascular /Diabetic Foot
- ☐ Stroke

Day - 2 January 24, 2015 - Main Session

- ☐ Interactive ECGs/Arrhythmia
- ☐ Atrial Fibrillation/ Arrhythmia
- ☐ Plenary Lectures
- ☐ CIMS-Oration
- ☐ Congenital Heart Disease / Structural
- ☐ Heart Failure
- ☐ Live Case Session

For more information / download Registration Form
www.jicindia.org



Conference Secretariat

CIMS Hospital, Nr. Shukan Mall, Off Science City Road, Sola, Ahmedabad-380060

Phone : +91-79-3010 1059 / 1060 Fax: +91-79-2771 2770

Email : communication@cimshospital.org, www.jicindia.org



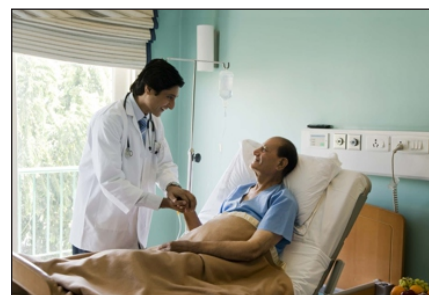
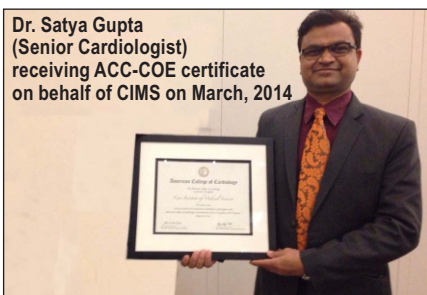
International
Centers
of Excellence
2014-2015

American College of Cardiology (ACC)
(Leading Institute of the World)
certifies CIMS Hospital as a
ACC - Center of Excellence



Amongst the first in World and India and only in Gujarat for high-standards of medical practice and dedication in providing quality cardiovascular care

Dr. Satya Gupta
(Senior Cardiologist)
receiving ACC-COE certificate
on behalf of CIMS on March, 2014



CIMS Express (Cardiology) - Same day appointment for new patient / second opinion

Call on 98250 66661, 079-3010 1008 (9 am to 5 pm) 98244 50000 (24 x 7)

CIMS Hospital : Nr. Shukan Mall, Off Science City Road, Sola, Ahmedabad-380060.

info@cims.me | www.cims.me

f /cimshospitals



KILL CANCER... A new hope

CIMS Cancer Center brings world's latest
Cancer technology to help you fight cancer

First time in Asia, Versa-HD for radiation therapy to treat wide
range of tumors and for treatment of highly complex cancers

Latest technology	Highly skilled oncologists	Efficient and personalized cancer solutions	Early detection and diagnosis
----------------------	-------------------------------	---	----------------------------------

Cancer Speciality Clinics

- | | | |
|-------------------------------|-----------------------------|---------------------------------|
| ◆ Head & Neck Cancer | ◆ Prostate & Bladder Cancer | ◆ Pediatric Cancer |
| ◆ Breast | ◆ Gynec Cancer | ◆ Muskuloskeletal (Bone Cancer) |
| ◆ Gastric & Colorectal Cancer | ◆ Thoracic Cancer | ◆ Neuro-Oncology (Brain Cancer) |



CIMS CANCER EXPRESS

For
**Radiotherapy/Chemotherapy/Surgery
Consultation, Second Opinion**

Same day appointment service
to serve you better
Daily OPD (Monday to Saturday)
9 am to 8 pm

Call for
Appointment **+91-99792 75555**
+91-79-3010 1257



**CIMS Hospital : Nr. Shukan Mall, Off Science City Road, Sola,
Ahmedabad-380060. Ph. : +91-79-2771 2771-75 (5 lines) Fax: +91-79-2771 2770**
info@cims.me | www.cims.me

Healthy Heart Registered under **RNI No. GUJENG/2008/28043**

Published on 5th of every month

Permitted to post at PSO, Ahmedabad-380002 on the 12th to 17th of every month under
Postal Registration No. **GAMC-1725/2012-2014** issued by SSP Ahmedabad valid upto 31st December, 2014
Licence to Post Without Prepayment No. **CPMG/GJ/97/2014** valid upto 31st December, 2014

If undelivered Please Return to :

CIMS Hospital, Nr. Shukan Mall,
Off Science City Road, Sola, Ahmedabad-380060.
Ph. : +91-79-2771 2771-75 (5 lines)
Fax: +91-79-2771 2770
Mobile : +91-98250 66664, 98250 66668

Subscribe "Healthy Heart" : Get your "Healthy Heart", the information of the latest medical updates only ₹ 60/- for one year.
To subscribe pay ₹ 60/- in cash or cheque/DD at CIMS Hospital Pvt. Ltd. Nr. Shukan Mall, Off Science City Road, Sola, Ahmedabad-380060. Phone : +91-79-3010 1059 / 3010 1060. Cheque/DD should be in the name of : **"CIMS Hospital Pvt. Ltd."**
Please provide your **complete postal address with pincode, phone, mobile and email id** along with your subscription

Care At Homes

home health @ your doorstep

For complete medical care at home

Medical | Nursing | Caregiver | Rehabilitation services

First time in Gujarat



CIMS Hospital :

Nr. Shukan Mall, Off Science City Road, Sola, Ahmedabad-380060.
Ph. : +91-79-2771 2771-75 (5 lines) Fax: +91-79-2771 2770
Email : info@cims.me Web : www.cims.me

- High quality medical care for safer recuperation
- 24-hour services, including all holidays and weekends
- Highly trained & experienced healthcare professionals
- If any of your patients require these services, just give them this number **+91-90990 67988** or **+91-81418 92999** we will take care of the rest.

**1 day to 1 month or
more home health care**

**JUST A SINGLE PHONE CALL
+91-90990 67988
+91-81418 92999
TO TAKE CARE OF YOUR NEEDS**

www.careathomes.com

CIMS Hospital Pvt. Ltd. | CIN : U85100GJ2001PTC039962 | info@cims.me | www.cims.me

Printed, Published and Edited by Dr. Keyur Parikh on behalf of the CIMS Hospital

Printed at Hari Om Printery, 15/1, Nagori Estate, Opp. E.S.I. Dispensary, Dudheshwar Road, Ahmedabad-380004.

Published from CIMS Hospital, Nr. Shukan Mall, Off Science City Road, Sola, Ahmedabad-380060.